Lower Extremity Reconstruction

Harvey Chim, MD FACS
Associate Professor
Division of Plastic and Reconstructive Surgery
University of Florida College of Medicine

Groin wounds

Groin wound

Hip wounds

Hip wound


HANES
HANES

New options in leg reconstruction

Lower extremity reconstruction

- Traditional reconstructive paradigm
- Propeller/ perforator flaps
- Reconstruction of foot defects

Traditional paradigm

- Proximal 1/3 leg: Gastrocnemius flap
- Middle 1/3 leg: Soleus flap
- Distal 1/3 leg: Free flap

In the past

- Distal 1/3 leg defect = Free flap


ADULT

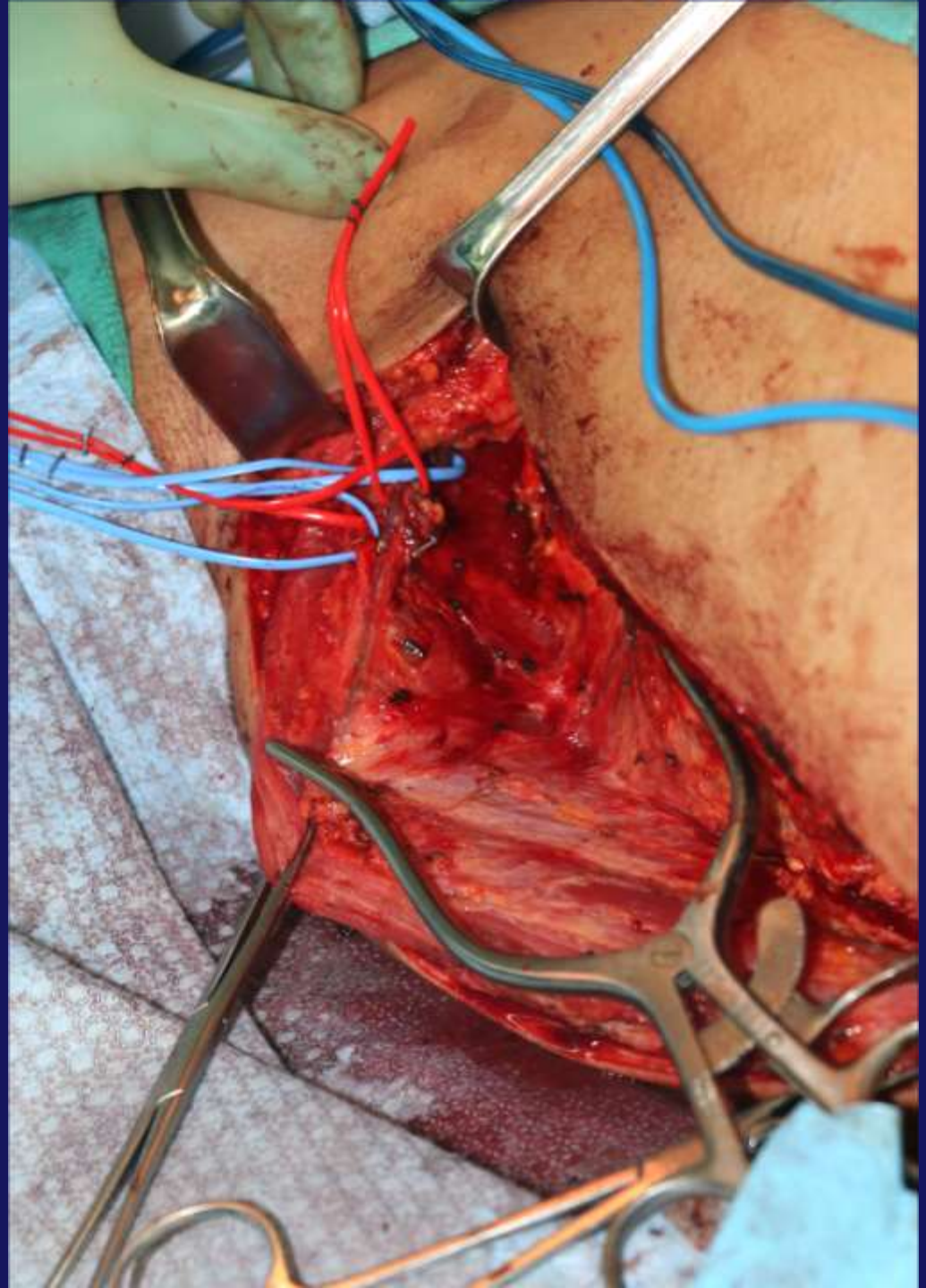

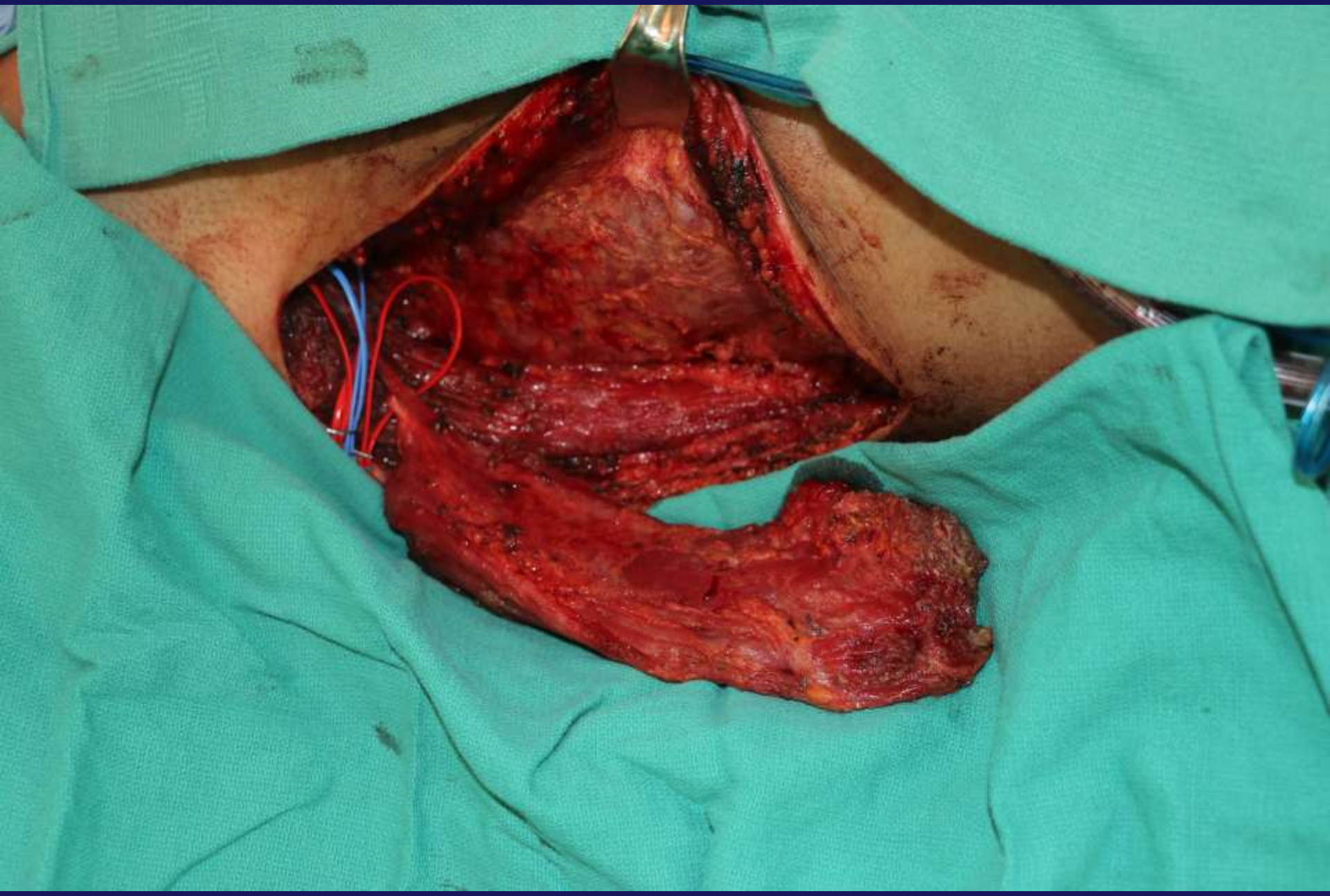

Title: Immediate application of VAC dressing over free muscle flaps in the lower extremity does not compromise flap survival and results in decreased flap thickness

Materials and Methods: Over a 19 month period, all consecutive free muscle flaps for lower extremity reconstruction at a Level I trauma center were evaluated prospectively for postoperative flap thickness, complications and flap survival. Immediate application of a VAC dressing was performed in 9 patients, while the flap was left exposed for monitoring in 8 patients.

Results: There was no statistically significant difference in flap survival between both cohorts. Mean flap thickness at postoperative day 5 for the VAC group was 6.4 $\pm$ 6.4 mm, while flap thickness for the exposed flap group was 29.6 $\pm$ 13.5 mm. Flap thickness was significantly decreased at postoperative day 5 for the VAC dressing group.

Conclusion: Immediate application of VAC dressing following free muscle flaps to the lower extremity does not compromise flap survival or outcomes and results in decreased flap thickness and a better aesthetic outcome.

Free Tissue Transfer with Distraction Osteogenesis Is Effective for Limb Salvage of the Infected Traumatized Lower Extremity

Harvey Chim, M.D.
John K. Sontich, M.D.
Bram R. Kaufman, M.D.

Cleveland, Ohio

Background: Salvage of acute and chronic tibial osseocutaneous defects in the lower extremity poses a formidable problem. Although local, distant, and free tissue transfer or bone grafting alone may be adequate for repair of small wounds or osseous defects, large or complicated defects necessitate a different approach. The authors describe their experience with free tissue transfer in combination with distraction osteogenesis for complex composite osteocutaneous defects.

Methods: The authors reviewed a consecutive series of 28 patients who underwent treatment over an 8-year period, with follow-up ranging from 1 to 8.5 years. Mean time to flap after injury was 1082 days (range, 6 days to 30 years). Indications for treatment included infected nonunion of the tibia ($n = 18$), acute traumatic bone loss ($n = 5$), skin and soft-tissue breakdown that occurred during distraction osteogenesis ($n = 4$), and exposed bone following previous failed free flap ($n = 1$).

Results: Free flaps used included the rectus abdominis ($n = 17$), latissimus dorsi ($n = 5$), gracilis ($n = 5$), and radial forearm ($n = 1$). Mean length of bone gap was 63 mm (range, 30 to 140 mm), and mean area of wound requiring flap coverage was 219 cm^2 (range, 35 to 400 cm^2). Twenty-five patients (89.3 percent) had successful flap coverage and went on to ambulate independently and return to work. The minor complication rate was 42.9 percent.

Conclusions: Distraction osteogenesis in combination with free tissue transfer is a powerful technique that allows limb salvage, particularly when local and regional flaps are unavailable or inadequate. For infected nonunion of the tibia, it permits a staged approach that allows underlying osteomyelitis to declare itself and provides vascularized healthy soft-tissue coverage that facilitates repeated operations for the purpose of distraction. (*Plast. Reconstr. Surg.* 127: 2364, 2011.)

Fig. 2. Case 1. (*Above, left*) Limb-length discrepancy with shortening of the left leg by 6 cm and persistent discharge. (*Above, right*) Defect resulting from débridement. (*Below, left*) Coverage with rectus free flap and split-thickness skin graft. (*Below, right*) Good soft-tissue coverage provided by free tissue transfer allows distraction osteogenesis.

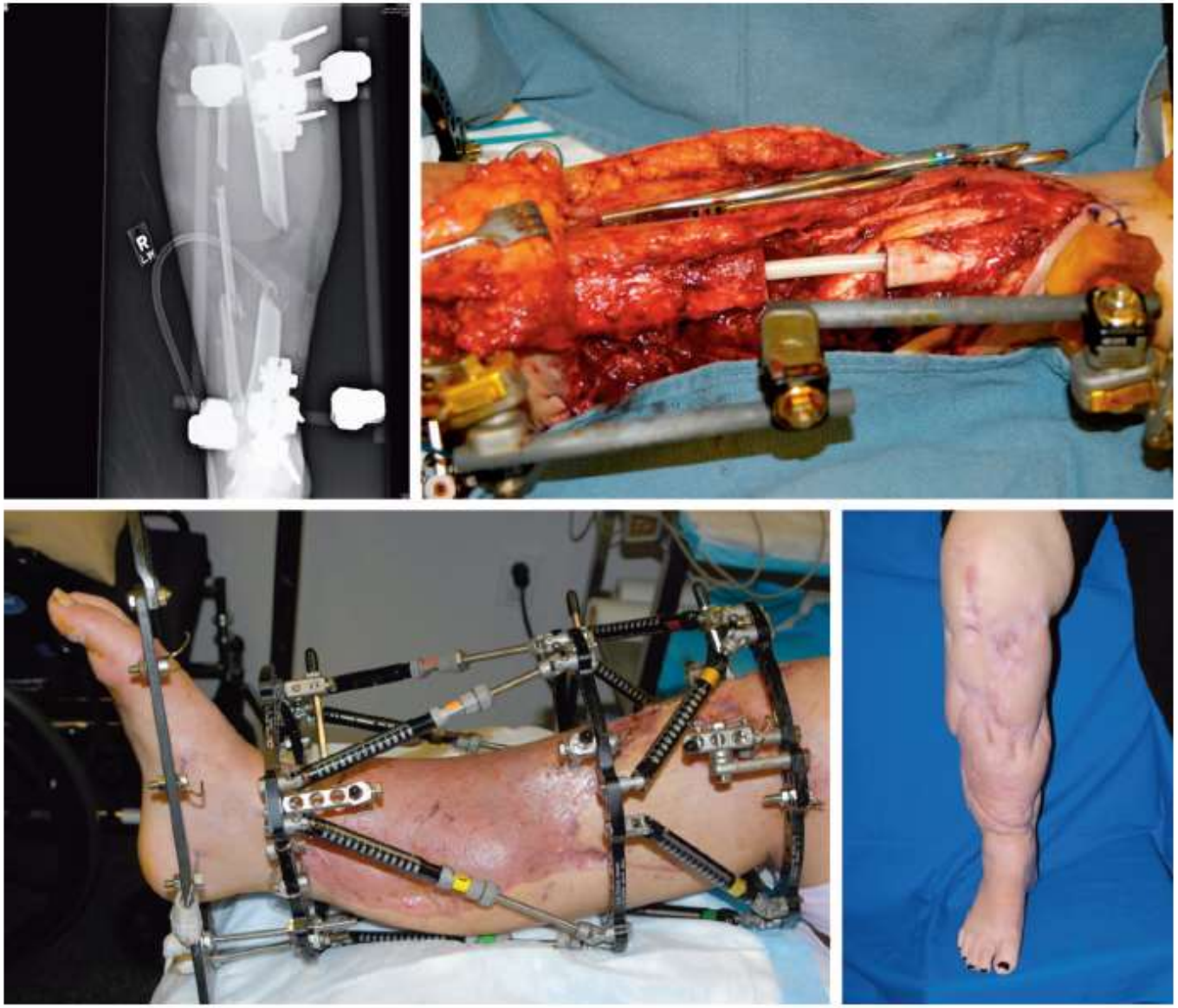

Fig. 4. Case 3. (*Above, left*) Initial radiograph shows fracture of the tibia and segmental fracture of the fibula. (*Above, right*) Soft-tissue defect after débridement. The bone gap has been stabilized with an antibiotic rod spacer and external fixator. A latissimus dorsi flap was used for soft-tissue coverage. (*Below, left*) Bone gap was stabilized with the Taylor Spatial Frame. (*Below, right*) All wounds had healed by completion of distraction osteogenesis.

Propeller & Perforator Flaps

Angiosomes

1987

Taylor and Palmer

"The angiosomes defined the tissues available for composite transfer."

British Journal of Plastic Surgery (1987), **40**, 113–141

The vascular territories (angiosomes) of the body: experimental study and clinical applications

G. I. TAYLOR and J. H. PALMER

Department of Plastic and Reconstructive Surgery, Royal Melbourne Hospital and Department of Anatomy, University of Melbourne

Summary—The blood supply to the skin and underlying tissues was investigated by ink injection studies, dissection, perforator mapping and radiographic analysis of fresh cadavers and isolated limbs. The results were correlated with previous regional studies done in this department.

The blood supply is shown to be a continuous three-dimensional network of vessels not only in the skin but in all tissue layers. The anatomical territory of a source artery in the skin and deep tissues was found to correspond in most cases, giving rise to the angiosome concept.

Arteries follow closely the connective tissue framework of the body. The primary supply to the skin is by direct cutaneous arteries which vary in calibre, length and density in different regions. This primary supply is reinforced by numerous small indirect vessels, which are "spent" terminal branches of arteries supplying the deep tissues.

An average of 374 major perforators was plotted in each subject, revealing that there are still many more potential skin flaps. Our arterial roadmap of the body provides the basis for the logical planning of incisions and flaps. The angiosomes defined the tissues available for composite transfer.

Angiosome Principle

- An angiosome is a 3 dimensional anatomic block of tissue (including skin, subcutaneous tissue, fascia, muscle and bone) fed by a source artery
- Each angiosome is linked to another by numerous choke, or collateral vessels

Neville RF, et al. Ann Vasc Surg 2009;23:367-373.

Angiosomes

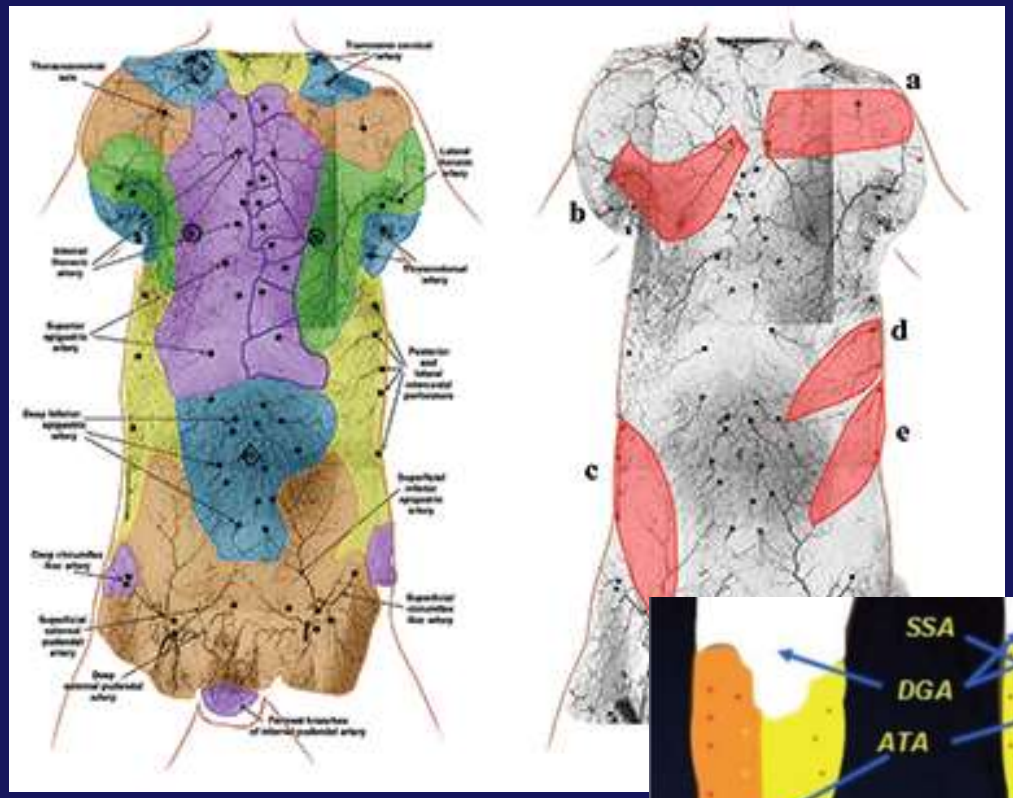

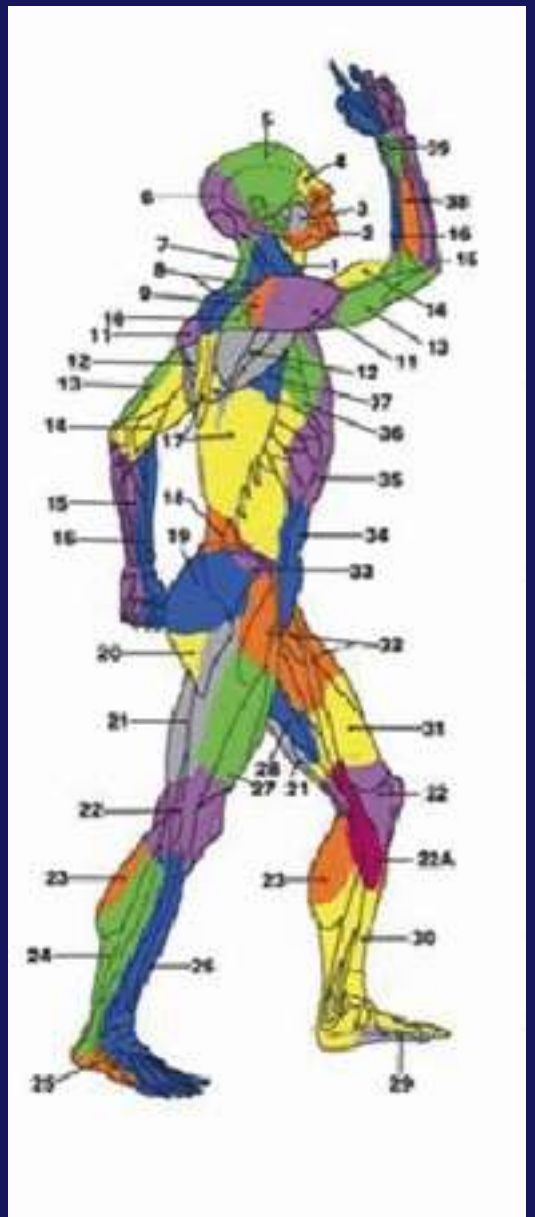

Angiosomes

- Define the safe clinical territory of flaps
- Perfused by a named (source) artery and vein
- Pedicled and free flaps

Perforasomes

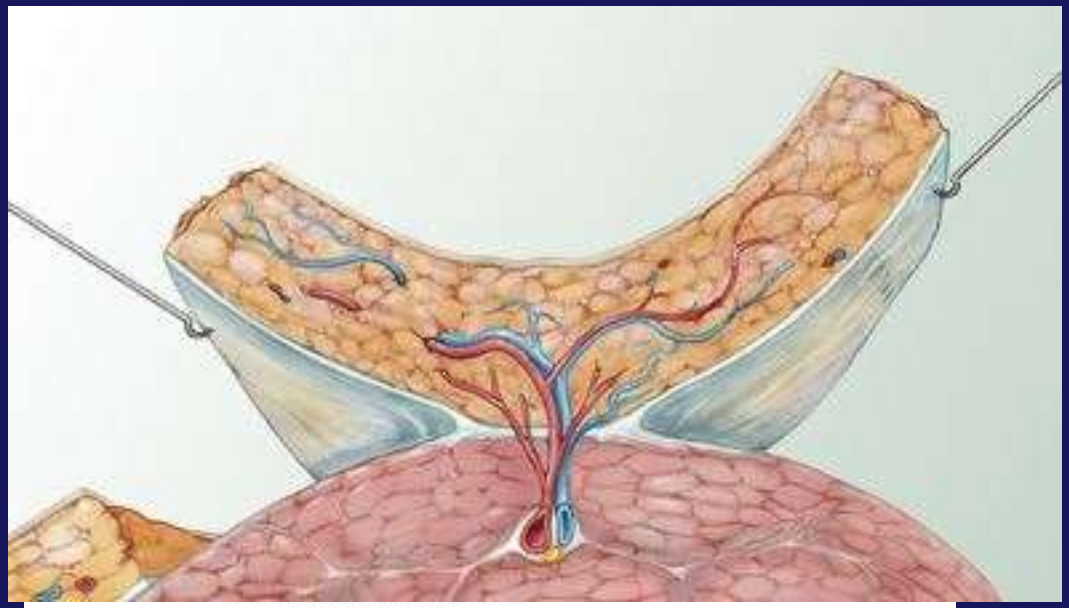

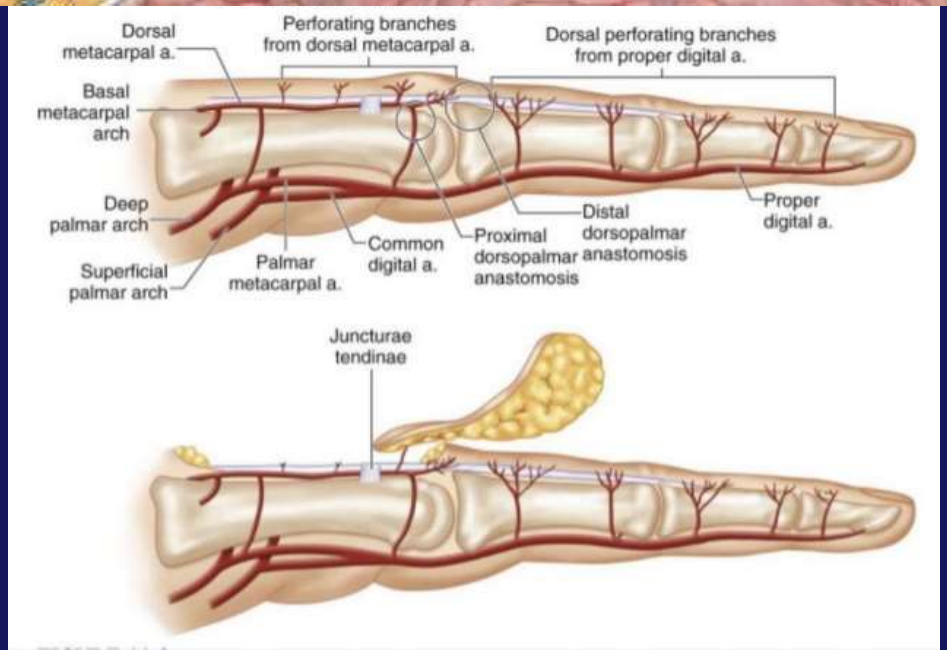

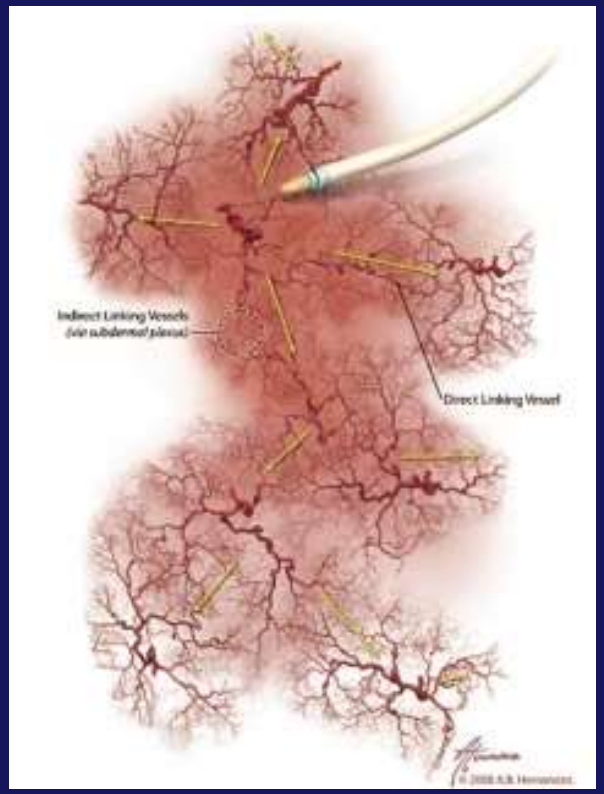

“Gent” consensus on perforator flap terminology (2001)

- A perforating vessel/ perforator is a vessel that has its origin in one of the axial vessels of the body and that passes through certain structural elements of the body, interstitial connective tissue and fat, before reaching the subcutaneous fat layer.

Perforator flaps

- Direct cutaneous
  - Only perforate deep fascia
- Indirect cutaneous
  - Traverse other structures before going through the deep fascia
    - Septocutaneous
    - Musculocutaneous

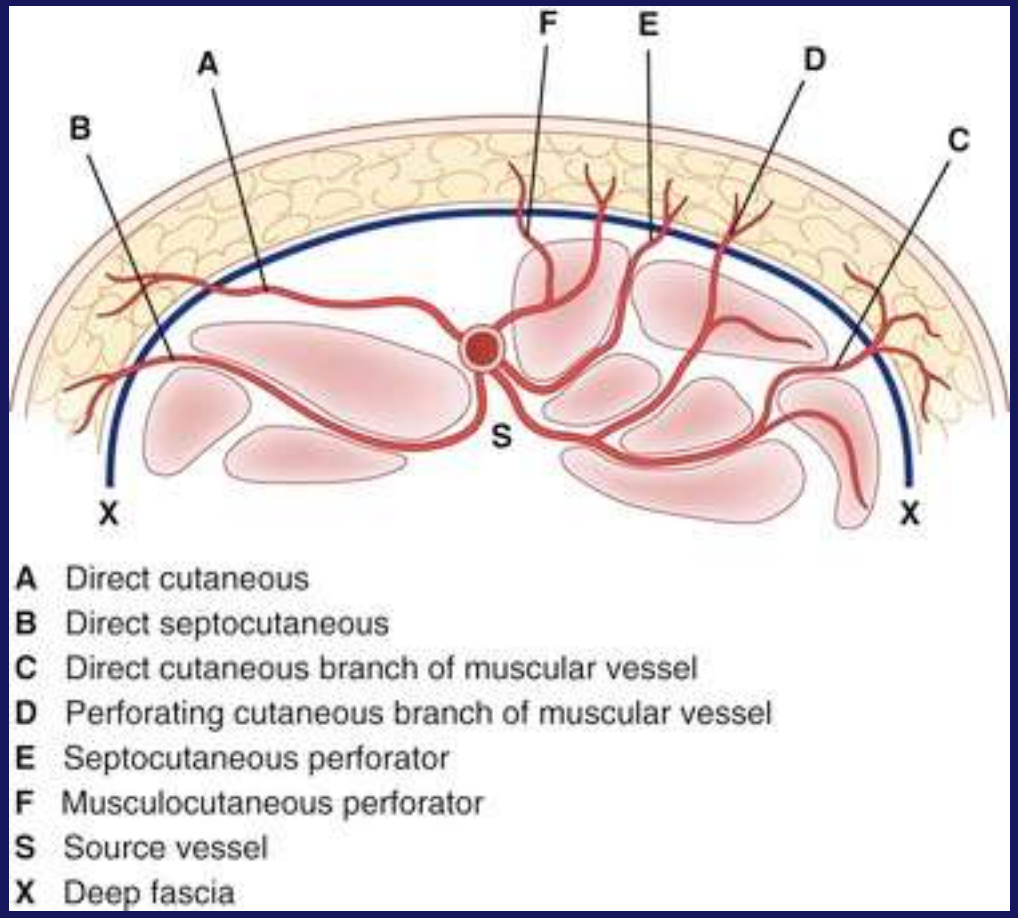

Pedicled perforator flaps

- Based on a single perforator
- Rotated in a fashion of a propeller- up to 180 degrees
- Propeller flaps
- Defined as an island flap that reaches the recipient site through an axial rotation

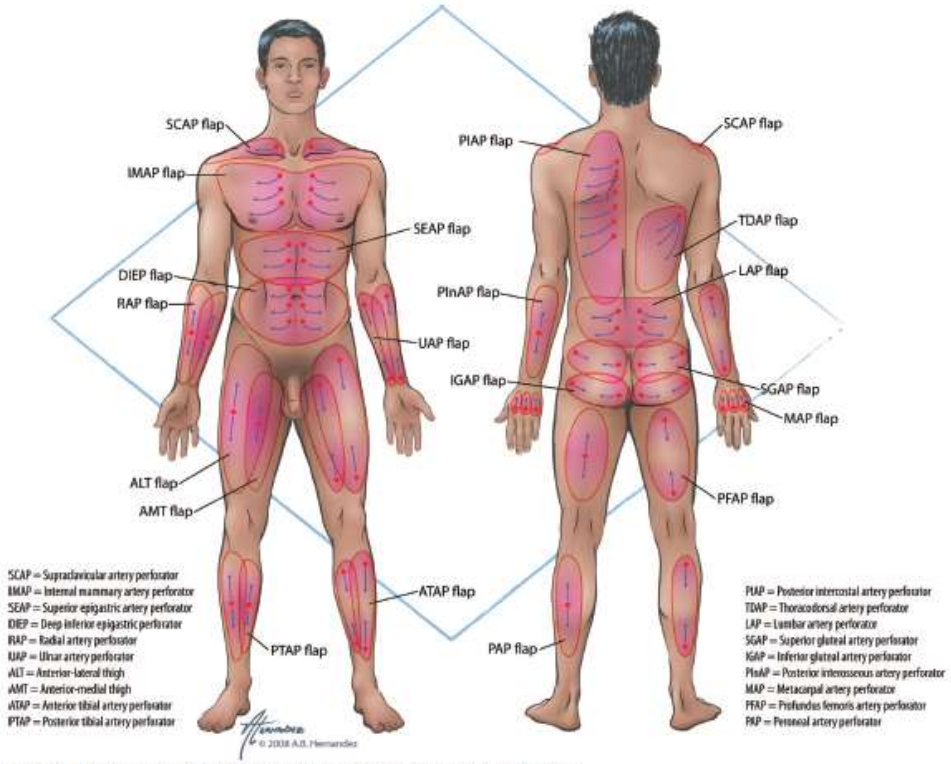

Fig. 17. Perforasomes of the body. Each perforator represents a possible flap.

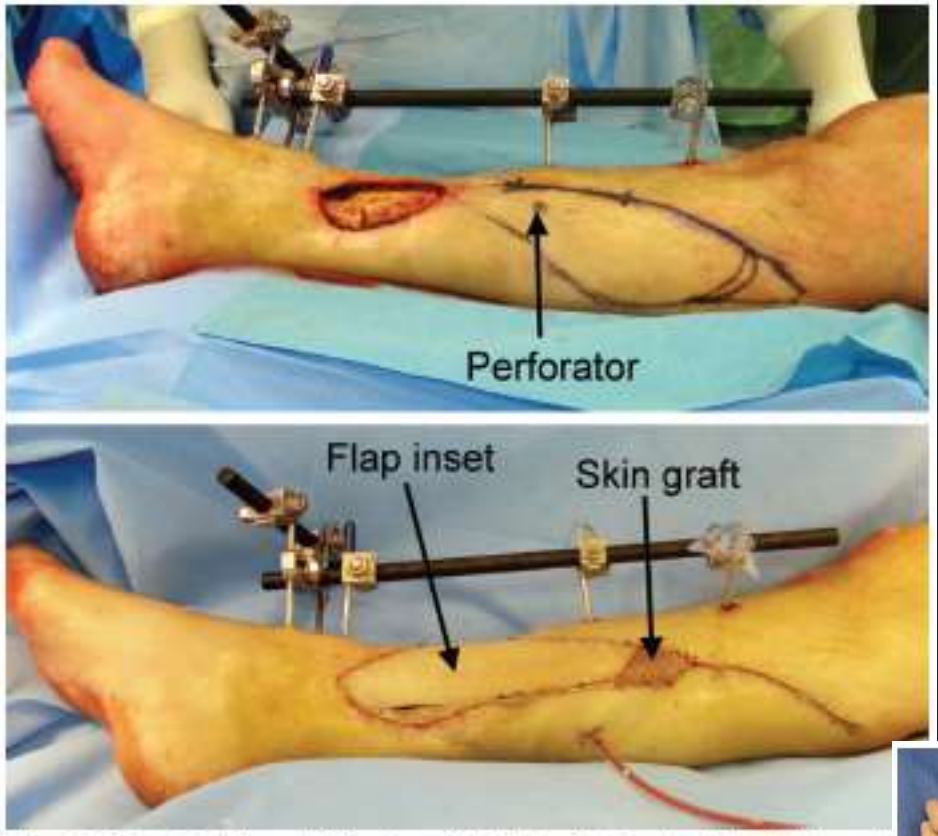

Fig. 12. Case 38. (*Above*) Defect on distal tibia. Perforator detected is mark
(*Below*) Pedicled propeller flap rotated 180 degrees and inset into defect. Do
site was closed partially with a skin graft.

Fig. 11. Case 27. (*Above, left*) Defect on forearm after excision of squamous cell carcinoma. (*Above, right*) An 8 × 3-cm propeller flap was designed based on a posterior interosseous artery perforator. (*Below left*) Flap was rotated 180 degrees for inset. (*Below right*) Flap inset, with primary closure of donor site.

Posterior tibial artery perforator flap

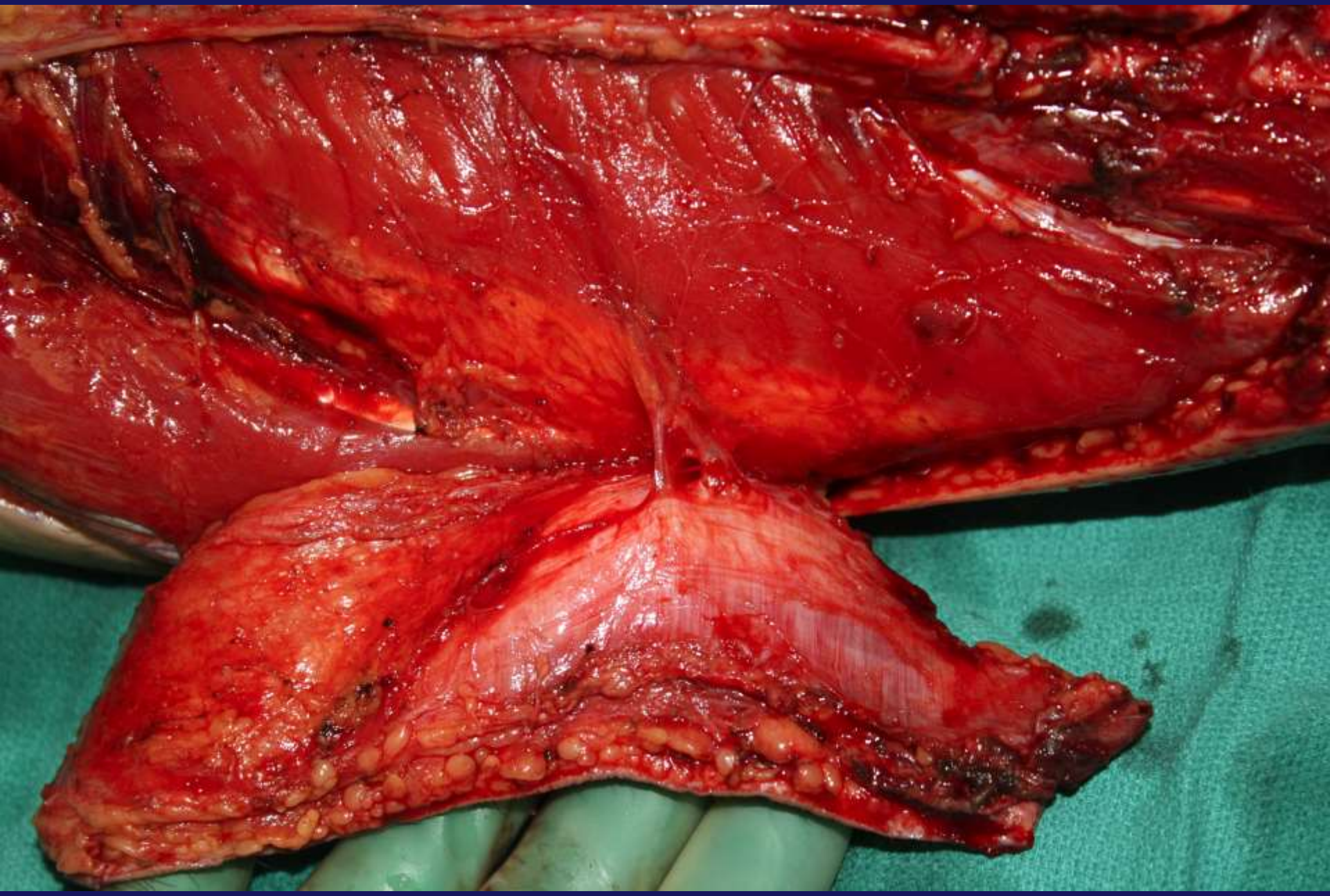


STEP

Peroneal artery perforator flap

Lateral supramalleolar flap

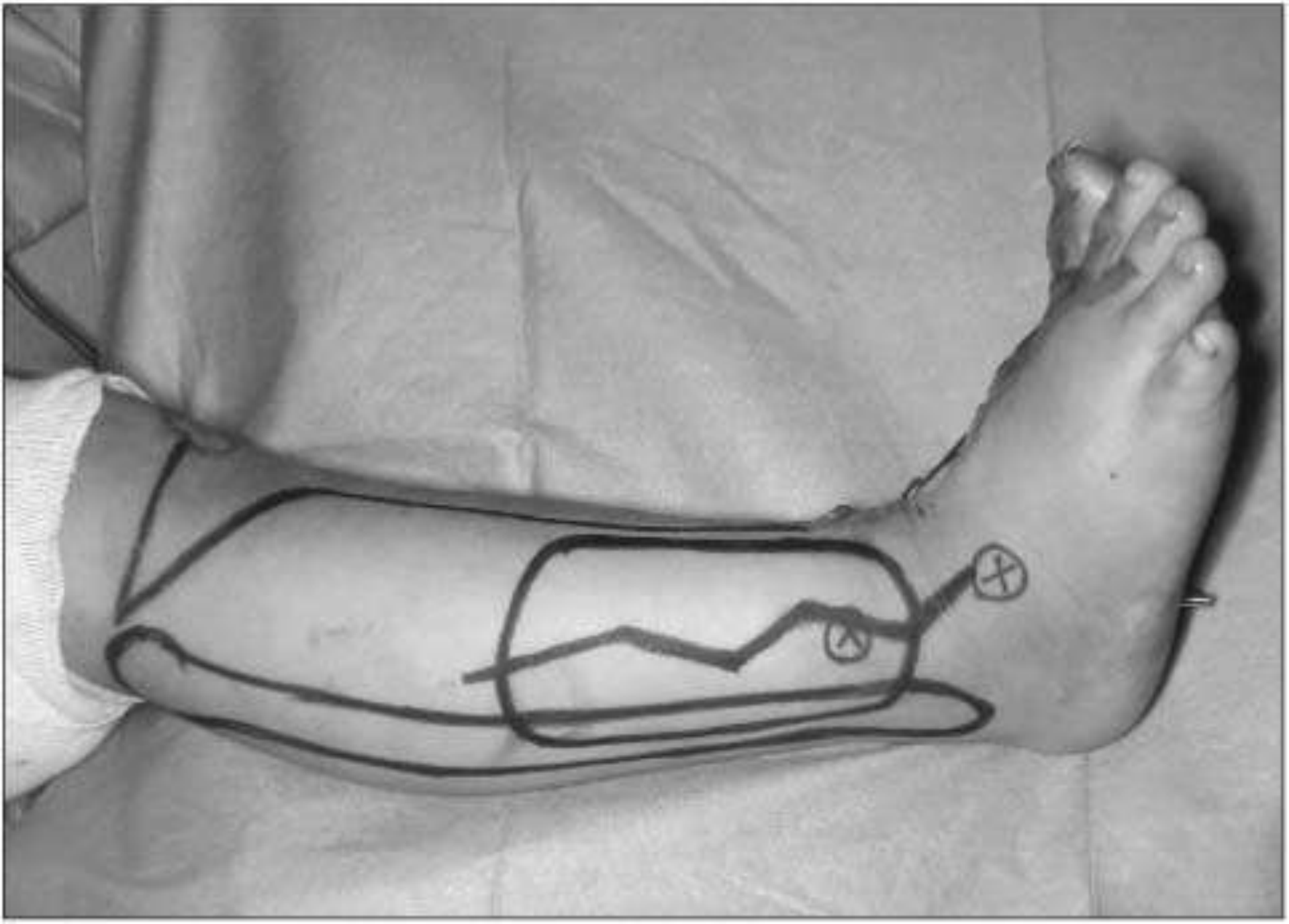

Dorsalis Pedis Flap


9X4.5

New free flaps

Medial sural artery perforator flap

The Medial Sural Artery Perforator Free Flap

Pedro C. Cavadas, M.D., Ph.D., Juan R. Sanz-Giménez-Rico, M.D., Arturo Gutierrez-de la Cámara, M.D., Ph.D., Angel Navarro-Monzonís, M.D., Santiago Soler-Nomdedeu, M.D., and Francisco Martínez-Soriano, M.D., Ph.D.

Valencia and Vigo, Spain

The medial sural artery supplies the medial gastrocnemius muscle and sends perforating branches to the skin. The possible use of these musculocutaneous perforators as the source of a perforator-based free flap was investigated in cadavers. Ten legs were dissected, and the topography of significant perforating musculocutaneous vessels on both the medial and the lateral gastrocnemius muscles was recorded. A mean of 2.2 perforators (range, 1 to 4) was noted over the medial gastrocnemius muscle, whereas in only 20 percent of the specimens was a perforator of moderate size noted over the lateral gastrocnemius muscle. The perforating vessels from the medial sural artery clustered about 9 to 18 cm from the popliteal crease. When two perforators were present (the most frequent case), the perforators were located at a mean of 11.8 cm (range, 8.5 to 15 cm) and 17 cm (range, 15 to 19 cm) from the popliteal crease. A series of six successful clinical cases is reported, including five free flaps and one pedicled flap for ipsilateral lower-leg and foot reconstruction. The dissection is somewhat tedious, but the vascular pedicle can be considerably long and of suitable caliber. Donor-site morbidity was minimal because the muscle was not included in the flap. Although the present series is short, it seems that the medial sural artery perforator flap can be a useful flap for free and pedicled transfer in lower-limb reconstruction. (*Plast. Reconstr. Surg.* 108: 1609, 2001.)

paid in the literature to the exact distribution of the cutaneous branches.

The concept of independent musculocutaneous perfusion (i.e., the muscle itself is not necessary for the vascularization of the skin island overlying it) was first suggested by Fujino in the sixties,[4] and it was later masterfully developed by Koshima and associates[5–8] and Kroll and Rosenfield,[9] giving birth to the so-called perforator flaps. This concept is gaining popularity because it allows transferring of the same skin territory as before, but without sacrificing the muscle, in a far more elegant manner.

The feasibility of using the medial sural artery musculocutaneous perforating branches to nourish a cutaneous flap was first investigated in cadavers and then in six clinical cases. On a thorough literature search, a similar flap was described as a pedicled flap in a free paper presented at the 90th Annual Scientific Assembly of the Southern Medical Association.[10] To the best of the authors' knowledge, no similar study has been published in the English literature, or at least as a free transfer.

Fig. 1. Preoperative markings: three lines should be marked in the calf region. A line is made along the popliteal crease, and the posterior midline (from the midpoint of the popliteal crease to the calcaneus) is marked. The third line is drawn along the distal border of the medial gastrocnemius muscle.

Fig. 2. The free medial sural artery perforator flap is elevated with two musculocutaneous perforators and its pedicle.


Cardinal Health

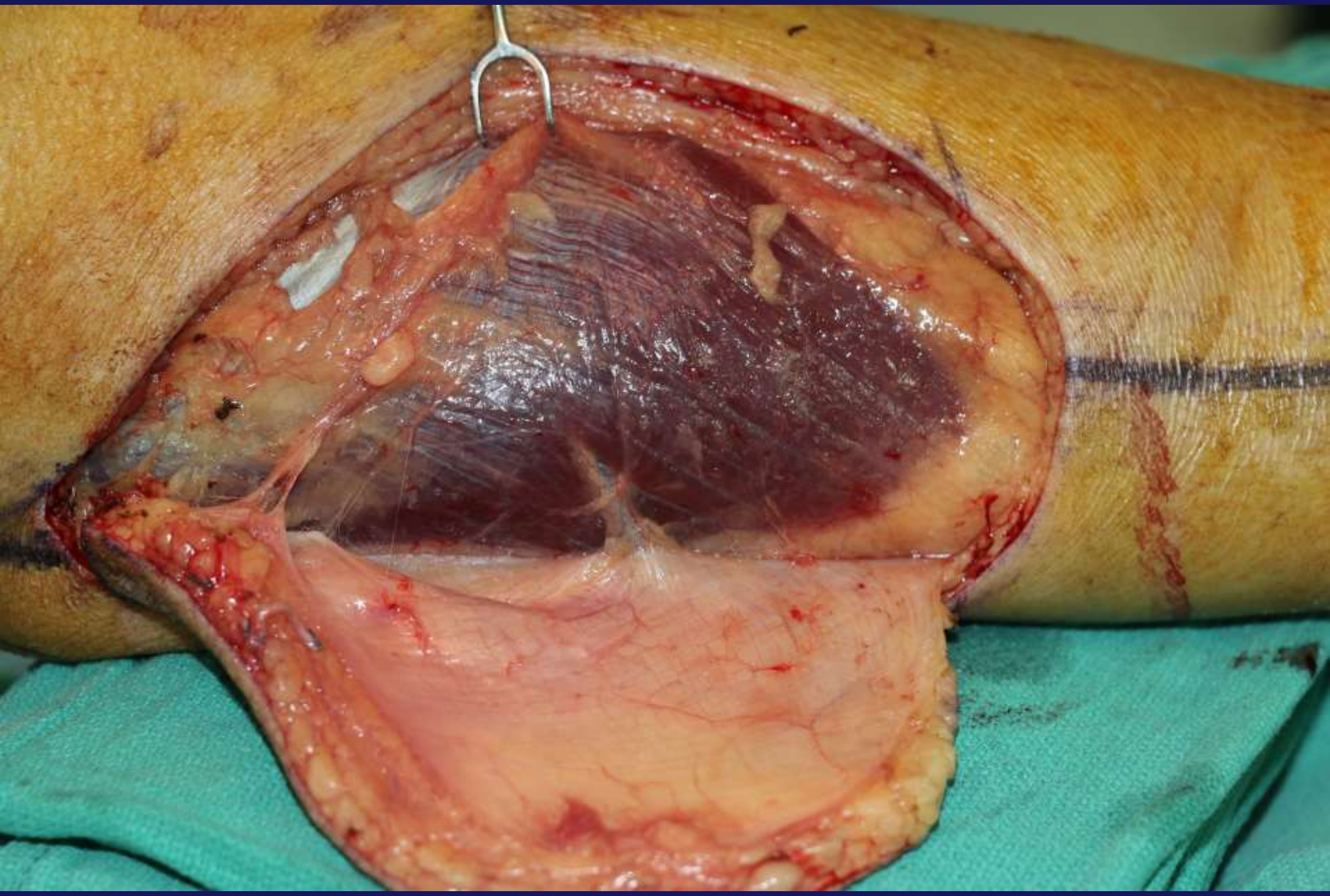

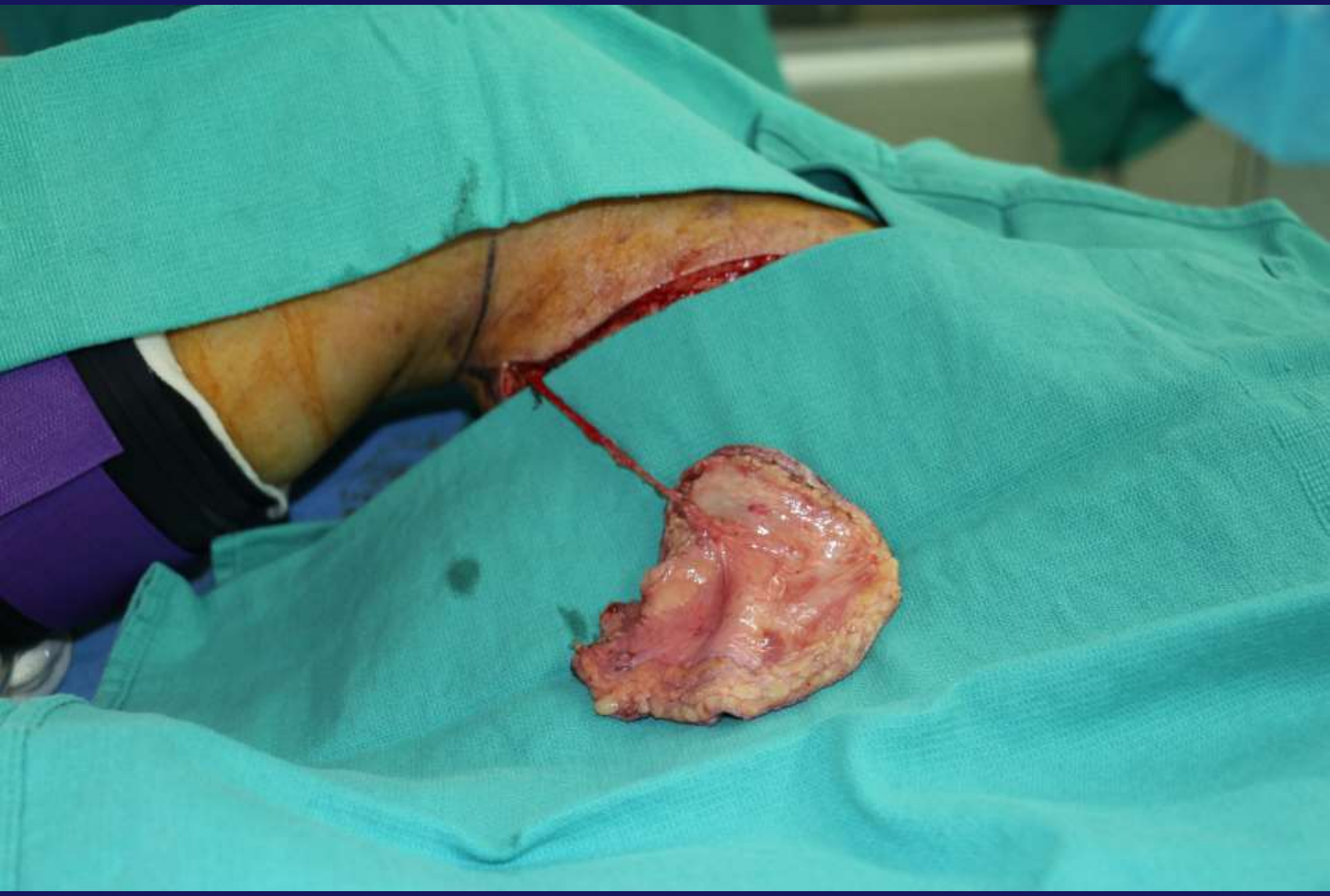

Metatarsal reconstruction


R


R
25
R
25
EXI: 431
Plate # 46933225 ST

Metatarsal Reconstruction with Use of Free Vascularized Osteomyocutaneous Fibular Grafts Following Resection of Malignant Tumors of the Midfoot

A Series of Six Cases

By Cyril D. Toma, MD, Martin Dominkus, MD, Martin Pfeiffer, MD, Pietro Giovanoli, MD, Ojan Assadian, MD, and Rainer Kotz, MD

Investigation performed at the Medical University of Vienna, Vienna, Austria

Background: Bone and soft-tissue sarcomas are uncommon, and their location in the foot is extremely rare. While limb salvage has become the standard of care in the treatment of sarcoma in an extremity, the unique anatomy of the foot presents challenges in reconstructing a viable and functional limb.

Methods: Between 1998 and 2005, we used free microvascularized osteomyocutaneous fibular grafts to reconstruct the defects created after extensive midfoot resection in six consecutive patients with a primary malignant tumor. In all but one patient, the extent of the resection involved at least two metatarsals. The mean age (and standard deviation) at the time of the operation was 30 ± 13 years. At the final follow-up examination, clinical and radiographic evaluations were performed on all patients, and functional outcome and quality of life were assessed with use of the Musculoskeletal Tumor Society score, the American Orthopaedic Foot and Ankle Society Score, and the Toronto Extremity Salvage Score.

Results: The median duration of follow-up was 52.2 months. Limb salvage was achieved in five patients. In the remaining patient, amputation was necessary because of flap failure. Revision surgery was necessary in all patients because of complications (skin ulcerations in three patients; hematoma in two patients; and infection, necrosis of the second toe, and flap necrosis in one patient each). At the time of final follow-up, five patients had satisfactory function and reported good quality of life. The average Musculoskeletal Tumor Society, American Orthopaedic Foot and Ankle Society, and Toronto Extremity Salvage scores were 82%, 75 points, and 92%, respectively. At the time of the final follow-up, five patients had no evidence of disease and one patient had disease.

Conclusions: Following the resection of a malignant tumor in the midfoot, the use of microvascularized osteomyocutaneous fibular grafts has proven to be a successful surgical technique, offering an alternative to ablative surgery with functional restoration of the salvaged limb.

Level of Evidence: Therapeutic Level IV. See Instructions to Authors for a complete description of levels of evidence.

Fig. 1-A

Figs. 1-A through 1-G Case 1, a twenty-one-year-old man with biphasic synovial sarcoma. **Fig. 1-A** Axial T1-weighted magnetic resonance image shows contact of the tumor with the first and second metatarsals. **Fig. 1-B** Radiograph of the surgical specimen, depicting the extent of resection (partial resection of the first and second metatarsal bones and total resection of the medial and intermediate cuneiform bones).

Fig. 1-B

Fig. 1-C

Fi

Fig. 1-G

Photograph of foot made at clinical examination ninety months postoperatively.

Fig. 2-A

Figs. 2-A through 2-F Case 4. A twenty-one-year-old man with alveolar rhabdomyosarcoma of the left foot. **Fig. 2-A** Preoperative lateral radiograph.

Fig. 2-B

Preoperative T1-weighted magnetic resonance image.

Fig. 2-C

Fig. 2-D

Fig. 2-C Radiograph of the surgical specimen, depicting the extent of the resection (total resection of the third and fourth metatarsals and partial resection of the cuboid and cuneiform bone). **Fig. 2-D** Dorsoplantar radiograph made one day postoperatively.

Fig. 2-F

Lateral weight-bearing radiograph of the involved (left) side and of the noninvolved (right) side.

Distal plantar defects

Retrograde-Flow Medial Plantar Island Flap Reconstruction of Distal Forefoot, Toe, and Webspace Defects

Charles E. Butler, MD
Pierre Chevray, MD, PhD

Plantar forefoot defects have been reconstructed using a wide variety of techniques, including skin grafts, local flaps, and free tissue transfer. The distally based, retrograde-flow medial plantar island flap provides coverage with durable plantar skin from the nonweight-bearing instep area to reconstruct defects at the metatarsal heads. This technique requires careful flap dissection, and the anterior reach of the flap is limited by its pedicle length and vascular pivot point location. The authors describe two cases using this flap for reconstruction of tumor resection defects (5 × 6 cm and 5 × 8 cm) involving the distal forefoot, toes, and webspaces. One case required venous supercharging of a congested flap with an interpositional vein graft. Technical aspects of the design, elevation, and inset of the flap that enhance its versatility and reliability are presented. The reverse-flow medial plantar fasciocutaneous island flap should be considered an option for forefoot defects that extend anteriorly onto the metatarsal heads, including defects involving the toes and webspaces.

Butler CE, Chevray P. Retrograde-flow medial plantar island flap reconstruction of distal forefoot, toe, and webspace defects. Ann Plast Surg 2002;49:196–201

From the Department of Plastic Surgery, The University of Texas M. D. Anderson Cancer Center, Houston, TX.

Received Nov 1, 2001, and in revised form Dec 5, 2001. Accepted for publication Dec 5, 2001.

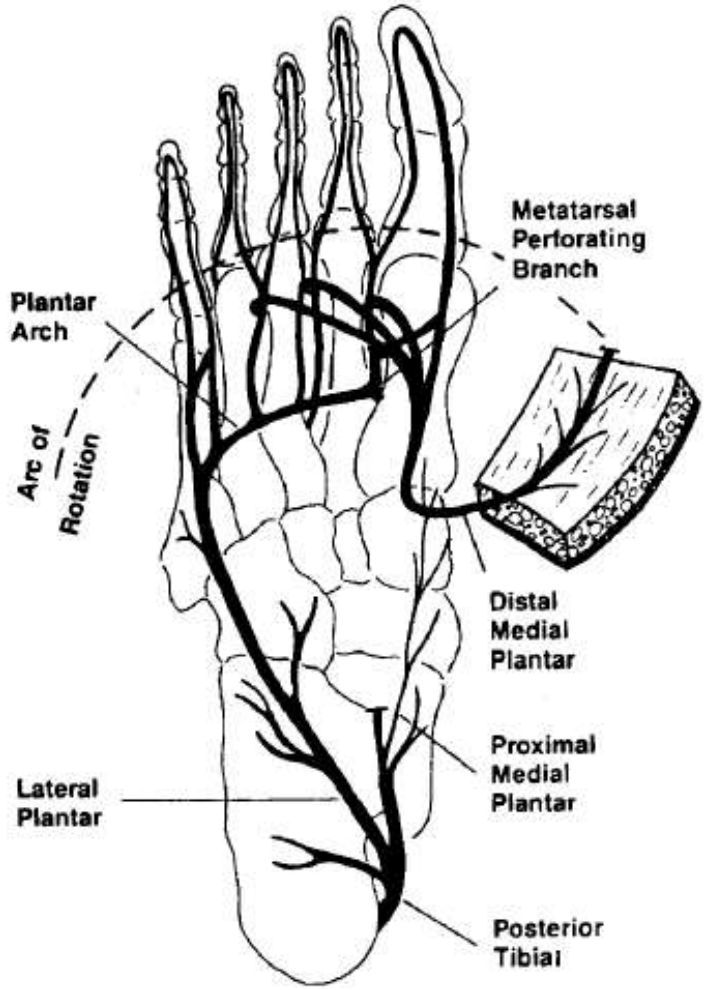

Fig 1. The diagram shows the plantar arterial anatomy. The retrograde-flow medial plantar artery island flap is supplied by communications from the first three plantar metatarsal arteries, which are branches of the deep plantar arch. The deep plantar arch receives contributions from both the lateral plantar artery and the deep plantar artery (metatarsal perforating branch of the dorsalis pedis). (Reprinted with permission from Baker GL, Newton ED, Franklin JD. Fasciocutaneous island flap based on the medial plantar artery: clinical applications for leg, ankle and forefoot. Plast Reconstr Surg 1990;85:47–58).

Conclusions

- New options for extremity reconstruction
- New options eg. propeller perforator flaps reduce morbidity and surgical time
- Early reconstruction results in better outcomes

Thank you!

Questions?

Email: harvey.chim@surgery.ufl.edu